



PRESENTING CLINICAL SIGNS

DATE History: Recheck degenerative valve disease. Receiving pimobendan 2.5 mg am, 1.25 mg pm. Asymptomatic.

2/14/23

ECHOCARDIOGRAPHIC FINDINGS

2D, M-mode, and Doppler study. This exam is compared to the one performed 3/21/22.

PERFORMED BY

Dr. Meredith Swart

INTERPRETED BY

Keith Blass, DVM,
MS, DACVIM
(Cardiology)

There is moderate left atrial dilation. The mitral valve leaflets are thickened and exhibit systolic prolapse. There is Doppler evidence of mitral regurgitation present. There is moderate left ventricular dilation. Left ventricular systolic function is hyperdynamic. The aorta and aortic are normal. Right atrial and right ventricular dimensions are normal. The tricuspid valve is normal. The pulmonary artery and pulmonic valve are normal. No pericardial effusion or cardiac masses are seen.

PATIENT

Peanut Fashingbauer

LA - 34.3 mm (prev. 31.4 mm)
LVIDd - 35.0 mm (prev. 31.9 mm)
LVIDs - 17.9 mm (prev. 14.8 mm)
FS - 48.9% (prev. 53.6%)
LVOT - 1.49 m/s (prev. 1.42 m/s)
RVOT - 1.08 m/s (prev. 1.01 m/s)

ASSESSMENT/RECOMMENDATIONS

Degenerative mitral valve disease

SPECIES

Canine

This examination demonstrates mild progression of Peanut's mitral valve disease over the past 11 months, as both her left atrial and left ventricular diameters have increased by three millimeters, and the chambers are now considered to be moderately dilated. Given this, Peanut's risk for the development of clinical signs secondary to her disease, such as coughing, exercise intolerance, syncope, and labored breathing, has increased mildly, and careful monitoring for these signs is recommended.

BREED

Dachshund Mix

No additional therapy has been proven to be beneficial at this stage of disease, therefore, no change in therapy is recommended at this time.

SEX

FS

A recheck echocardiogram is recommended in 6-9 months. Thoracic radiographs are recommended if Peanut experiences respiratory clinical signs.

AGE

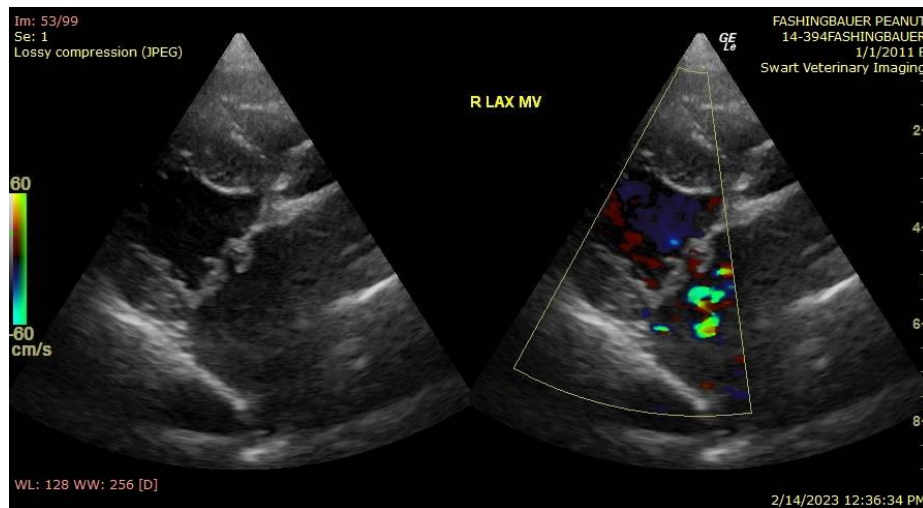
12 y

WEIGHT

13 lb

HOSPITAL NAME

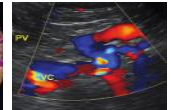
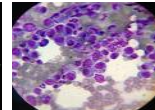
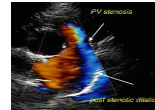
Swart Veterinary
Imaging



REFERRING VET

Dr. Swart

The information and recommendations provided are based on the images presented by the



DATE referring veterinarian. No evaluation can be communicated regarding pathology that was not visible in the image/video clips provided.

2/14/23 Thank you for this referral. If the clinical or image interpretation does not parallel your findings or if I can be of any further assistance please contact me.

PERFORMED BY Keith Blass, DVM, MS, DACVIM (Cardiology)
Dr. Meredith Swart KeithBlass@gmail.com
631-804-5754

INTERPRETED BY
Keith Blass, DVM,
MS, DACVIM
(Cardiology)

PATIENT
Peanut Fashingbauer

SPECIES
Canine

BREED
Dachshund Mix

SEX
FS

AGE
12 y

WEIGHT
13 lb

HOSPITAL NAME
Swart Veterinary
Imaging

REFERRING VET
Dr. Swart